

Changes of meniscal interhorn distances: An in vivo magnetic resonance imaging study[☆]

Demetrios S. Mastrokalos^a, Panayiotis J. Papagelopoulos^{a,*}, Andreas F. Mavrogenis^a,
Michael E. Hantes^b, Theofilos S. Karachalios^b, Hans H. Paessler^c

^aFirst Department of Orthopaedics, Athens University Medical School, ATTIKON Hospital, Athens Greece

^bDepartment of Orthopaedics, School of Health Sciences, University of Thessalia, Larissa, Greece

^cCenter for Knee and Foot Surgery-Sport Traumatology, ATOS Clinic Heidelberg, Heidelberg Germany

Received 2 February 2005; received in revised form 18 March 2005; accepted 29 March 2005

Abstract

The aim of this study was to evaluate the changes of the internal (IID) and external meniscal interhorn distance (EID) of the medial and the lateral meniscus under loading. Sagittal magnetic resonance images of 15 knees were studied. The medial and lateral meniscus were examined with the knee at 0° and 30° of flexion, under no load, with load equal to 50% of body weight and with load equal to 100% of body weight. Under no load, the mean IID was 19.9 mm for the medial meniscus and 12.3 mm for the lateral meniscus and the mean EID was 44.6 mm for the medial meniscus and 34.4 mm for the lateral meniscus. Under load equal to 50% and 100% of patient's body weight, there was a significant increase in both distances ($p < 0.05$). Under constant loading, flexion of the knee from 0° to 30°, decreased the EID of both menisci. In conclusion, loading increases both IID and EID. Knee position affects only the EID. The quality of magnetic resonance images may affect the reliability of such measurements.

© 2005 Elsevier B.V. All rights reserved.

Keywords: Magnetic resonance imaging; Knee joint; Meniscus; Deformation; Interhorn distance

1. Introduction

The menisci are essential anatomical structures with an important biomechanical role. Their function includes joint congruity and load-sharing, transmission of 40% to 70% of the load applied across the knee joint, stress absorption, joint lubrication and nutrition and secondary stabilization by limiting extremes in flexion and extension [1–3]. To perform these functions effectively they have a dynamic role. Loss of a meniscus leads to degenerative changes in 20% to 80% of the patients [1]. After total meniscectomy,

the coefficient of friction is increased by 20%. This accounts for the rapidly progressive degenerative changes.

Previous studies investigating the biomechanical behaviour of the menisci under different loading conditions and at different positions of the knee joint have been performed [1–3,5–7]. However, most of these studies have been conducted on cadavers. In the present study, intact human knees were examined with magnetic resonance imaging (MRI), to observe and measure changes of the internal and external interhorn distance of both menisci under different loads and in different knee positions.

2. Materials and methods

Twenty healthy volunteers (12 men and 8 women) were recruited and a total of 20 knees with no known abnormality were studied, using a low-field-strength magnetic resonance imaging unit (ESAOTE, Genoa, Italy). The low field strength (0.18 T) of

[☆] Conflict of interest statement: None of the authors have any financial and personal relationships with other people or organisations that could inappropriately influence (bias) their work.

* Corresponding author. Tel./fax: +30 011 30 210 672 1355.

E-mail address: pjp@hol.gr (P.J. Papagelopoulos).

this unit allows the joint position and loading to be changed rapidly by the investigator. An earlier prospective study did not show any difference in sensitivity and specificity between high- and lower-field-strength images [8].

The mean age of the volunteers was 30 years. Their mean body weight was 68 kg and mean height 174 cm. None of the volunteers had a history of knee injury. All the knees were anatomically intact, without any evidence of meniscal disorders. The MR images of 5 volunteers were degraded by artefacts due to movement by the subjects and were excluded from the study. The MR images of the remaining 15 intact knees were available for analysis. No abnormal pathology was identified in the soft tissues, bone, ligaments or menisci of any of the knees scanned.

A specially constructed balance was bolted to the foot support of the MRI apparatus to allow the knee to be scanned through an arc of 0° to 30° of flexion while loading. The seat was fixed to rule-out movement artefacts and movement out of the image volume. Foam cushions were placed between the knee of the subject and the MR surface coil, and a thermoplastic shell was moulded to the back of the thigh. The foot support and attached balance could be moved along a rail provided by the manufacturer of the machine, to enable the knees to be studied in 0° and 30° of flexion. The knee was supported in the frame to control and prevent movement artefacts. Previous studies performed by Nietert [9] have shown that these angles are representative of the limits of knee position in the stance phase of normal walking and running.

2.1. MR investigation: parameters and sections

To prevent movement artefacts during the loading conditions, a fast spin-echo technique (TE 16 ms, TR 560 ms) was employed. A field of view of 256×128 was combined with a 128×128 pixel matrix. The section thickness was 4 mm with an intersection gap of 0.5 mm. Five sagittal sections were imaged in each medial and lateral meniscus. First, a 10 mm thick axial scout image was obtained at the level of the joint space; this was used for the determinations of the sections over the medial and lateral tibial condyles. The five sagittal sections were placed in the medial and the lateral meniscus, at right angles to the posterior border of the lateral tibial plateau.

Each subject's foot was placed in the support, with the foot and ankle in neutral position; the knee joint and the seat were fixed as described above. Knee position was set by sliding the foot support in a groove and checking with a goniometer. Loading under 50%

and 100% of the subject's body weight was kept constant by the subject counterpressing vertically on the measuring platform of the balance, with an assistant exerting pressure from the other side and monitoring the weight display.

The medial and lateral meniscus were examined with the knee at 0° and 30°, under no load, with load equal to 50% of body weight and with load equal to 100% of body weight.

2.2. Evaluation

Each observer made three consecutive measurements of the parameters and the mean values were obtained. The measurements were repeated on a subsequent day, in order to assess the intra-observer reliability.

First, the medial-to-lateral scans of the medial meniscus and the lateral-to-medial scans of the lateral meniscus were screened to establish the section producing complete separation of the anterior and posterior horns. Then, a working line was drawn parallel to the tibial plateau, tangential to the subchondral bone. The internal interhorn distance (IID) was measured as the minimum distance between the posterior and anterior horns that is always parallel to the working line in the section chosen. The external interhorn distance (EID) was measured as the maximum distance between the anterior and posterior horn, parallel to the working line (Fig. 1).

2.3. Statistical analysis

The statistical analysis of the data was performed using Excel spreadsheet software, Version 97 (Microsoft, Seattle, USA) and the Statistical Package for Social Sciences, Release 6.1.3 for Windows (SPSS GmbH, Munich, Germany). Descriptive statistics (frequency and distribution functions) were computed and the working hypotheses tested. For related samples, the *t*-test (two-tailed) was used, while the Mann–Whitney *U*-test and the Wilcoxon test were used for unrelated samples. A significance level of 0.05 was adopted. Pearson's correlation was computed.

3. Results

3.1. Inter- and intra-observer reliability

Inter- and intra-observer reliability was determined using one parameter, the internal interhorn distance (IID) of the medial

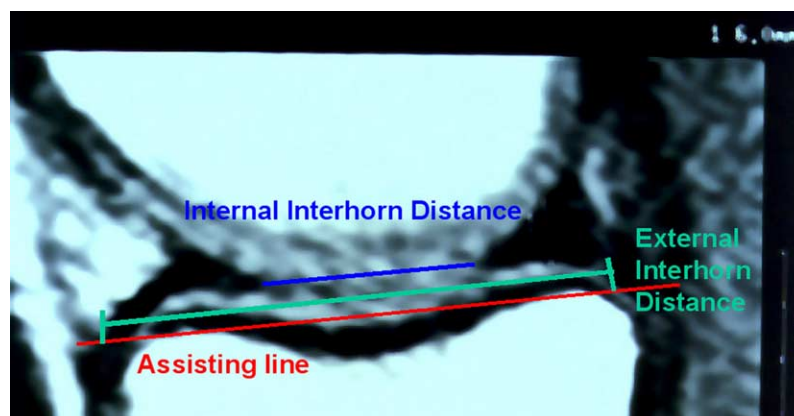
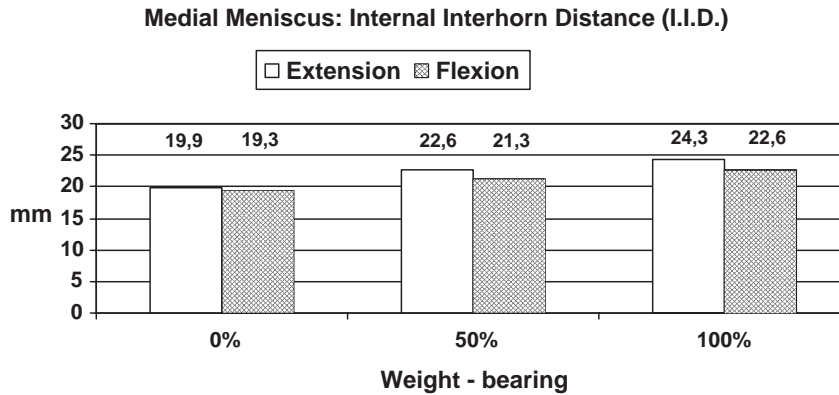


Fig. 1. Evaluation of the IID and EID. The distances are always parallel to the working line.



Graphic 1. Medial meniscus: mean IID under different loading and angles of flexion.

meniscus. The Pearson’s coefficient of correlation between the two observers was 0.48, showing a poor inter-observer reliability. The intra-observer reliability of observer No 1 was high (Pearson’s Coefficient: 0.81). Observer No 2, who was less experienced, had an intra-observer reliability of 0.66. Therefore, the results obtained by observer No 2 were rejected, and the analysis was conducted using only the results obtained by observer No 1.

3.2. Internal interhorn distance (IID)

The pattern of the internal distance between the anterior and posterior meniscal horns (IID) is shown in Graphics 1 and 2. In knee extension, an increase in loading from 0% to 50% of the body weight resulted in a statistically significant increase in the IID by 2.7 mm in the medial meniscus and by 0.6 mm in the lateral meniscus. The difference between non-weight-bearing and full-weight-bearing was 4.4 mm in the medial meniscus and 1.7 mm in the lateral meniscus. With the knee in 30° of flexion there was also an increase in the IID when loading was raised from 0% to 50% of the body weight. The IID between the horns of the medial meniscus increased by 2.0 mm, while that between the horns of the lateral meniscus increased by 0.9 mm. The difference between non-weight-bearing and full-weight-bearing was 3.3 mm in the medial and 2.2 mm in the lateral meniscus. These results were statistically significant for both menisci ($p < 0.05$) (Table 1).

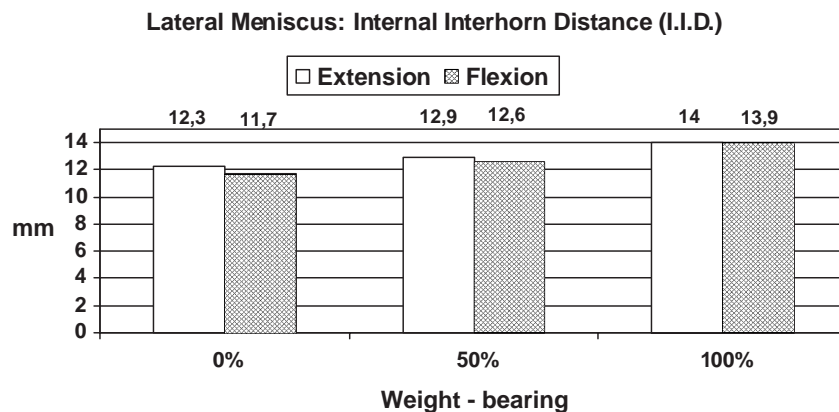
With constant loading at 0%, 50% and 100% of the body weight respectively, changing the knee position from extension to 30° of flexion resulted in a reduction of the IID. This was

the case both for the medial and lateral meniscus. Except for the fully loaded medial meniscus ($p < 0.05$), this decrease in the IID with 30° of flexion was not statistically significant (Graphics 1 and 2).

All sets of loading and knee positioning showed that the mean IID and the differences in these distances were constantly greater in the medial than in the lateral meniscus.

3.3. External interhorn distance (EID)

The pattern of change in the EID between the anterior and the posterior meniscal horns is shown in Graphics 3 and 4. As the loading was increased from 0% to 50% of the body weight, the EID of both menisci was found to increase both in extension (medial meniscus: 0.5 mm and lateral meniscus 0.7 mm) and in 30° of flexion (medial meniscus: 0.6 mm and lateral meniscus: 0.5 mm). Except for the increase in the lateral meniscus in 30° of flexion, all increases in the EID were statistically significant. Increasing the loading from 50% to 100% of the of the body weight resulted in a further statistically significant increase in the EID, both in extension (medial meniscus: 0.6 mm and lateral meniscus 0.7 mm) and in 30° of flexion (medial meniscus: 0.8 mm). In the lateral meniscus there was a decrease by 0.4 mm when the knee was in 30° of flexion. However, this decrease was not statistically significant. With constant loading (at 0%, 50% and 100% of the body weight, respectively), changing the knee position from extension to 30° of flexion resulted in a comparable amount of reduction in the EID in both menisci. While this



Graphic 2. Lateral meniscus: mean IID under different loading and angles of flexion.

Table 1
Differences and statistical significance of mean IID under different loading and angles of flexion in millimeters

	Medial meniscus			Lateral meniscus		
	0%–50%	50%–100%	0%–100%	0%–50%	50%–100%	0%–100%
0°	2.7 ($p=0.000$)	1.7 ($p<0.001$)	4.4 ($p=0.000$)	0.6 ($p<0.025$)	1.1 ($p<0.056$) ^a	1.7 ($p<0.003$)
30°	2.0 ($p=0.000$)	1.3 ($p<0.014$)	3.3 ($p=0.003$)	0.9 ($p<0.002$)	1.3 ($p=0.000$)	2.2 ($p=0.000$)

^a No statistical significance.

reduction was in all cases less than 1 mm, it was statistically significant (Graphics 3 and 4, Table 2).

In all sets of loading and knee positioning, the mean EID was greater in the medial than in the lateral meniscus. Equally, the associated differences were greater in the medial than in the lateral meniscus (Table 2).

4. Discussion

Magnetic resonance imaging is an established modality to study the anatomy and the disorders of the menisci. The sensitivity of the method in detecting meniscal tears ranges from 89% to 100% for the medial and 73% to 90% for the lateral meniscus. The specificity ranges from 72% to 92% for the medial and from 74% to 88% for the lateral meniscus [10,11].

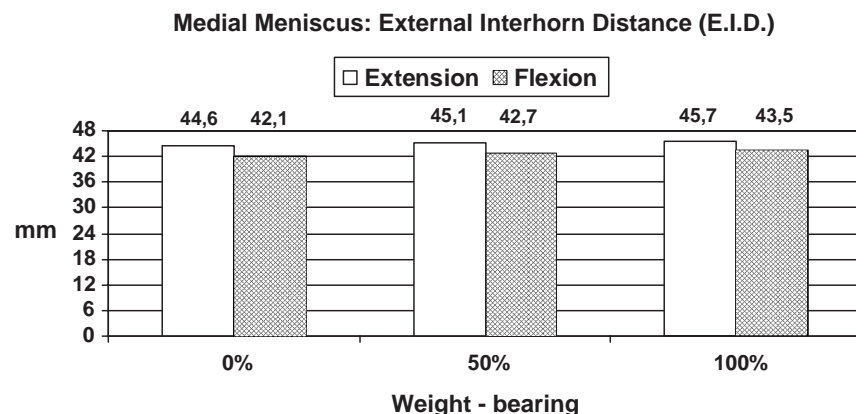
Both the MR imaging technique and the actual measurement method are important. The parameters to be measured must be well defined and determined in advance. The MR images should be obtained and the measurements should be performed by experienced investigators to preclude false results and, hence, erroneous conclusions. Our analysis of inter- and intra-observer reliability bears out these difficulties. In the examination of different subjects, differences in contrast, brightness or magnification are not entirely avoidable and are an inherent problem of the method described. Having multiple measurements performed by a larger number of experienced investigators may be a way of overcoming this difficulty.

Most previous studies have been hindered by disruption of the normal anatomy to allow direct visualization. Poor

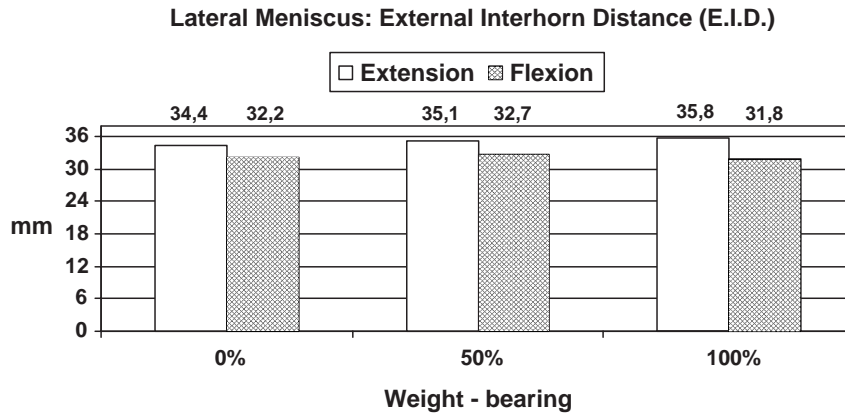
imaging techniques were used and studies were often performed on cadaver knees. However in cadaveric studies, extensive dissection of vital structural elements of the knee joint may affect the results obtained [4,5]. As reported by Kohn et al, [6] the removal of the knee capsule and ligaments will slightly alter the compression pattern in the intact menisci. Vedi et al [12] performed an in vivo study of meniscal movement in normal knees under load using an open MR scanner, allowing imaging in physiological positions in near to real time. The present study also involved an in-vivo investigation of meniscal movement and interhorn distances in normal human knee joints.

With constant knee position and increased loading, there was a significant increase in the internal interhorn distance in both menisci. This increase was greater in the medial than in the lateral meniscus. Renstroem and Johnson [1] described the peripheral extrusion of the menisci as the joint compression rises. Lengsfeld et al [7] measured the IID after the removal of all the knee stabilizers and also found the IID to increase in both menisci with increased knee joint loading. The greater IID of the medial, as compared with the lateral meniscus is most probably due to the anatomical shape of the tibial condyles. The concave shape of the medial tibial condyle tends to force the medial meniscus out of the joint space [13], whereas the convex shape of the lateral tibial condyle provides only a small tibiofemoral contact area, leaving sufficient space in the periphery for the lateral meniscus.

Under constant loading, by moving the knee from extension to 30° of flexion, the IID decreased. This decrease was greater in the medial than in the lateral meniscus. Since the radii of curvature of the femoral condyles become



Graphic 3. Medial meniscus: mean EID under different loading and angles of flexion.



Graphic 4. Lateral meniscus: mean EID under different loading and angles of flexion.

smaller posteriorly, the tibiofemoral contact area will be smaller in 30° of flexion than it is in extension. In addition, as shown in the studies of Ahmed and Burke [14] and Walker and Erkman [15], the anterior and posterior horns will be forced less far apart than they are in extension. The combination of shorter condylar radii and the different medial and lateral tibial plateau shapes would account for the different patterns of internal and external interhorn distance increase and decrease. Also, the anterior horn, which subluxates anteriorly in extension, is reduced when the knee is taken into 30° of flexion and follows the femoral condyles and thus the posterior horn, in a posterior direction [13,16].

The above explanation also serves to account for the significant increase in the external interhorn distance of both menisci in extension and 30° of flexion with increased loading. The increase was almost the same in the medial and the lateral meniscus and markedly smaller than the increase in the IID. This finding is accounted by the presence of the joint capsule, which blocks any further radial extrusion. The decrease in the EID of the lateral meniscus in 30° of flexion with an increase in loading from 50% to 100% of body weight was not statistically significant. This may be due to the greater mobility and smaller radius of curvature of the lateral femoral condyle. Also, the reduction in the EID with constant loading and flexion from 0° to 30° may be explained in terms of the more pronounced curvature of the femoral condyles and the associated smaller tibiofemoral contact area [14,15,17].

The IID and EID of the medial meniscus were consistently greater than those of the lateral meniscus. This finding may be accounted for by the posteromedial attach-

ment of the medial meniscus to the posterior oblique ligament and by the fact that the medial meniscus is less mobile than the lateral one [3,16]. As a result of this anatomical pattern, the lateral meniscus will follow the lateral femoral condyle as a unit, whereas the medial meniscus is tethered posteromedially and will follow the femoral condyle with its anterior and posterior horns gripping the condyle like a pincer.

The lateral displacement of the menisci has been investigated and measured in a number of studies [3,4,12,18]. In these studies bone landmarks were used and most of the authors found a statistically significant radial displacement of the menisci. The results of these studies may be indirectly compared with the results of the present study regarding the internal and external interhorn distances. However, the current study is an in vivo study and the meniscal deformation was measured with reference to the menisci, rather than to bone landmarks.

The menisci, in order to protect the articular surface from compressive stresses, must resist extrusion from the joint space as load is applied. Movement of the meniscus during knee flexion ensures maximal congruency with the articulating surfaces while avoiding injury to it [12,15]. The soft tissue attachments of the menisci are most substantial at the posterior horns, especially the medial meniscus, and therefore movement is restricted here. This provides stability, preventing anterior tibial translation impacting like “wheel-blocks” against the posterior femoral condyles. The relative immobility of the posterior part of the medial meniscus may account for the frequency with which this part is torn. Being fixed, it may be loaded more than other parts of the meniscus making it vulnerable to tears [12,15].

Table 2 Differences and statistical significance of mean EID under different loading and angles of flexion in millimeters

	Medial meniscus			Lateral meniscus		
	0%–50%	50%–100%	0%–100%	0%–50%	50%–100%	0%–100%
0°	0.5 (<i>p</i> <0.014)	0.6 (<i>p</i> <0.003)	1.1 (<i>p</i> =0.000)	0.7 (<i>p</i> =0.000)	0.7 (<i>p</i> <0.023)	1.4 (<i>p</i> =0.000)
30°	0.6 (<i>p</i> <0.001)	0.8 (<i>p</i> <0.012)	1.4 (<i>p</i> =0.000)	0.5 (<i>p</i> <0.062) ^a	– 0.9 (<i>p</i> <0.561)*	– 0.4 (<i>p</i> <0.785)*

^a No statistical significance.

The approach described in the present study could also be used in the growing number of patients receiving meniscal transplants [19,20]. The method lends itself to the monitoring of the postoperative course and the eventual outcome, concerning always that correct graft sizing is crucial to the success of the procedure [19,21]. MRI can readily show the morphology and position of the transplanted meniscus, and may prove useful in the identification of both immediate and long-term complications [22,23]. In a study, [24] MRI findings after meniscal transplantation were correlated with those at clinical, arthroscopic and histological examination. MRI enabled accurate assessment of allograft attachments. Allograft degeneration was indicated by an increase of signal intensity. Verstraete et al [25] found a large overlap of MRI findings in patients with poor, good, and excellent clinical outcome. MRI does not predict the clinical outcome in every case. This finding is supported by van Arkel et al [26] who concluded that the correlation between clinical results, arthroscopy and MRI could be improved by more sophisticated MRI techniques. Both the MRI examination and re-look arthroscopy cannot provide a dynamic evaluation of the meniscus, for example the function of the meniscus allograft under weight bearing conditions.

The data obtained in the present study should make possible to monitor meniscal healing and the outcome of meniscus re-fixation. Since the various techniques currently available differ greatly in their complexity and costs, there is an urgent need for a comparison of these modalities.

References

- [1] Renström P, Johnson RJ. Anatomy and biomechanics of the menisci. *Clin Sports Med* 1990;9:523–38.
- [2] Fithian DC, Kelly MA, Mow VC. Material properties and structure–function relationships in the menisci. *Clin Orthop* 1990;252:19–31.
- [3] Thompson WO, Thaete FL, Fu FH, Dye SF. Tibial meniscal dynamics using three-dimensional reconstruction of magnetic resonance images. *Am J Sports Med* 1991;19:210–6.
- [4] Bylski–Austrow DI, Ciarelli MJ, Kayner DC, Matthews LS, Goldstein SA. Displacements of the menisci under joint load: an in vitro study in human knees. *J Biomech* 1994;27:421–31.
- [5] Fukuda Y, Takai S, Yoshino N, Murase K, Tsutsumi S, Ikeuchi K, et al. Impact load transmission of the knee joint–influence of leg alignment and the role of meniscus and articular cartilage. *Clin Biomech (Bristol, Avon)* 2000 (Aug);15(7):516–21.
- [6] Boyd KT, Myers PT. Meniscus preservation; rationale, repair techniques and results. *Knee* 2003 (Mar);10(1):1–11.
- [7] Boxheimer L, Lutz AM, Treiber K, Goepfert K, Crook DW, Marincek B. MR imaging of the knee: position related changes of the menisci in asymptomatic volunteers. *Invest Radiol* 2004 (May);39(5):254–63.
- [8] Vallet AD, Lee DH, Munk PL, Hewett L, Eliasziw M, Dunlavy S, et al. Anterior cruciate ligament tear: prospective evaluation of diagnostic accuracy of middle-and high-field-strength MR imaging at 1.5 and 0.5 T. *Radiology* 1995;197:826–30.
- [9] Nietert M. The human knee joint as a biomechanical problem. *Biomed Tech (Berl)* 1977;22(1–2):13–21.
- [10] Elvenes J, Jerome CP, Reikeras O, Johansen O. Magnetic resonance imaging as a screening procedure to avoid arthroscopy for meniscal tears. *Arch Orthop Trauma Surg* 2000;120(1–2):14–6.
- [11] Justice WW, Quinn SF. Error patterns in the MR imaging. Evaluation of menisci of the knee. *Radiology* 1995;196:617–21.
- [12] Vedi V, Williams A, Tennant SJ, Spouse E, Hunt DM, Gedroyc WMW. Meniscal movement. An in-vivo study using dynamic MRI. *J Bone Jt Surg (Br)* 1999;81-B:37–41.
- [13] Pinar H, Akseki D, Bozkurt M, Karaoglan O. Dislocating anterior horn of the medial meniscus. *Arthroscopy* 1998;14(3):246–9.
- [14] Ahmed AM, Burke DL. In vitro measurement of static pressure distribution in synovial joints: I. Tibial surface of the knee. *J Biomech Eng* 1983;105:216–25.
- [15] Walker PS, Erkman MJ. The role of the menisci in force transmission across the knee. *Clin Orthop* 1975;109:184–92.
- [16] Aagaard H, Verdonk R. Function of the normal meniscus and consequences of meniscal resection. *Scand J Med Sci Sports* 1999 (Jun);9(3):134–40.
- [17] Kapandji IA. The physiology of the joints: annotated diagrams of the mechanics of the human joints. Edinburgh, Churchill Livingstone.
- [18] Kenny C. Radial displacement of the medial meniscus and Fairbank's signs. *Clin Orthop* 1997;339:163–73.
- [19] Amoczky SP, Cooper TG, Stadelmaier DM, Hannafin JA. Magnetic resonance signals in healing menisci: an experimental study in dogs. *Arthroscopy* 1994;10:552–7.
- [20] Felix NA, Paulos LE. Current status of meniscal transplantation. *Knee* 2003;10:13–7.
- [21] Noyes FR, Barber-Westin SD, Rankin M. Meniscal transplantation in symptomatic patients less than fifty years old. *J Bone Jt Surg (Am)* 2004;86-A:1392–404.
- [22] Peters G, Wirth CJ. The current state of meniscal allograft transplantation and replacement. *Knee* 2003 (Mar);10(1):19–31 [Review].
- [23] Patten RM, Rolfé BA. MRI of meniscal allografts. *J Comput Assist Tomogr* 1991;19(2):243–6.
- [24] Potter HG, Rodeo SA, Wickiewicz TL, Warren RF. MR imaging of meniscal allografts: correlation with clinical and arthroscopic outcomes. *Radiology* 1996 (Feb);198(2):509–14.
- [25] Verstraete KL, Verdonk R, Lootens T, Verstraete P, De Rooy J, Kunnen M. Current status and imaging of allograft meniscal transplantation. *Eur J Radiol* 1997 (Dec);26(1):16–22.
- [26] van Arkel ERA, Goei R, de Ploeg I, de Boer HH. Meniscal allografts: evaluation with magnetic resonance imaging and correlation with arthroscopy. *Arthroscopy* 2000;16(5):517–21.